BOCA
BOLETIM DE CONJUNTURA

CORRELATION BETWEEN LABORATORY AND HISTOPATHOLOGICAL FINDINGS IN BILATERAL RENAL DISEASE IN A HORSE: A CASE REPORT

CORRELAÇÃO ENTRE ACHADOS LABORATORIAIS E HISTOPATOLÓGICOS EM DOENÇA RENAL BILATERAL EM EQUINO: RELATO DE CASO

CORRELACIÓN ENTRE HALLAZGOS LABORATORIALES E HISTOPATOLÓGICOS EN ENFERMEDAD RENAL BILATERAL EN EQUINO: REPORTE DE CASO

https://doi.org/10.56238/bocav25n81-005

Data de submissão: 13/07/2026 **Data de publicação:** 13/08/2026

Fernanda Ponchini de Paula[1], Thaylla Maria Ferreira[2], João Marcos Liporini[3], Alef Winter Oliveira Alvarenga[4], Caio Rafael Siqueira Vasconcelos[5], Fernanda Gosuen Gonçalves Dias[6], Lucas de Freitas Pereira[7], Maysa Barbosa de Almeida[8]

ABSTRACT

Renal diseases in horses are relatively uncommon; however, they are clinically significant due to their frequently delayed diagnosis and guarded prognosis. This study reports a case of bilateral renal disease in a horse, correlating the clinical, laboratory, and histopathological findings. An adult horse was presented with a history of abdominal pain, dysuria, and biochemical abnormalities consistent with azotemia, as evidenced by increased serum urea and creatinine concentrations. Despite the therapeutic interventions instituted, the animal showed progressive clinical deterioration and was subsequently euthanized. During necropsy, both kidneys were collected for histopathological evaluation. Microscopically, lesions consistent with chronic kidney disease were observed, including glomerulosclerosis, interstitial fibrosis, mononuclear inflammatory infiltrate, and tubular atrophy, associated with acute changes such as tubular degeneration and necrosis, tubular dilation, and abundant intratubular calcium carbonate crystals. The correlation between the laboratory and histopathological findings allowed a comprehensive assessment of the extent of renal damage and established the definitive diagnosis of bilateral renal disease with concurrent acute and chronic lesions. This case highlights the importance of integrating clinical evaluation, laboratory testing, and histopathological examination in the investigation of

[1] Undergraduate Student in Veterinary Medicine. University of Franca.
E-mail: ponchinifer@gmail.com
[2] Veterinarian. University of Franca. E-mail: thayllaferreira01@hotmail.com
[3] Veterinarian. University of Franca. E-mail: joaomliporini@hotmail.com
[4] Veterinarian. University of Franca. E-mail: winteralef@gmail.com
[5] PhD Candidate in Science. Institution: University of Franca. E-mail: siqueiravasconcelos@hotmail.com
[6] PhD in Science. University of Franca. E-mail: fernanda.dias@unifran.edu.br
[7] PhD in Science. University of Franca. E-mail: lucas.pereira@unifran.edu.br
[8] PhD Candidate in Science. University of Franca. E-mail: maysaa@unifran.edu.br

equine nephropathies, emphasizing the role of microscopic analysis in characterizing renal lesions and elucidating disease progression.

Keywords: Azotemia. Glomerulosclerosis. Interstitial Fibrosis. Tubular Necrosis. Nephropathy.

RESUMO

Doenças renais em equinos são relativamente incomuns; entretanto, são clinicamente significativas devido ao seu diagnóstico frequentemente retardado e prognóstico reservado. Este estudo relata um caso de doença renal bilateral em um equino, correlacionando os achados clínicos, laboratoriais e histopatológicos. Um equino adulto foi apresentado com histórico de dor abdominal, disúria e anormalidades bioquímicas consistentes com azotemia, evidenciado pelo aumento das concentrações séricas de ureia e creatinina. Apesar das intervenções terapêuticas instituídas, o animal apresentou deterioração clínica progressiva e foi posteriormente eutanasiado. Durante a necropsia, ambos os rins foram coletados para avaliação histopatológica. Microscopicamente, foram observadas lesões consistentes com doença renal crônica, incluindo glomerulosclerose, fibrose intersticial, infiltrado inflamatório mononuclear e atrofia tubular, associadas com alterações agudas como degeneração tubular e necrose, dilatação tubular e abundantes cristais de carbonato de cálcio intratubulares. A correlação entre os achados laboratoriais e histopatológicos permitiu uma avaliação abrangente da extensão do dano renal e estabeleceu o diagnóstico definitivo de doença renal bilateral com lesões agudas e crônicas concomitantes. Este caso destaca a importância de integrar avaliação clínica, testes laboratoriais e exame histopatológico na investigação de nefropatias equinas, enfatizando o papel da análise microscópica na caracterização de lesões renais e na elucidação da progressão da doença.

Palavras-chave: Azotemia. Glomerulosclerose. Fibrose Intersticial. Necrose Tubular. Nefropatia.

RESUMEN

Las enfermedades renales en equinos son relativamente infrecuentes; sin embargo, son clínicamente significativas debido a su diagnóstico frecuentemente retrasado y pronóstico reservado. Este estudio reporta un caso de enfermedad renal bilateral en un equino, correlacionando los hallazgos clínicos, de laboratorio e histopatológicos. Un equino adulto fue presentado con antecedentes de dolor abdominal, disuria y anomalías bioquímicas consistentes con azoemia, evidenciado por el aumento de las concentraciones séricas de urea y creatinina. A pesar de las intervenciones terapéuticas instituidas, el animal mostró un deterioro clínico progresivo y fue posteriormente eutanasiado. Durante la necropsia, ambos riñones fueron recolectados para evaluación histopatológica. Microscópicamente, se observaron lesiones consistentes con enfermedad renal crónica, incluyendo glomerulosclerosis, fibrosis intersticial, infiltrado inflamatorio mononuclear y atrofia tubular, asociadas con cambios agudos tales como degeneración tubular y necrosis, dilatación tubular y abundantes cristales de carbonato de calcio intratubulares. La correlación entre los hallazgos de laboratorio e histopatológicos permitió una evaluación integral de la extensión del daño renal y estableció el diagnóstico definitivo de enfermedad renal bilateral con

lesiones agudas y crónicas concurrentes. Este caso destaca la importancia de integrar la evaluación clínica, las pruebas de laboratorio y el examen histopatológico en la investigación de nefropatías equinas, enfatizando el papel del análisis microscópico en la caracterización de lesiones renales y en la elucidación de la progresión de la enfermedad.

Palabras clave: Azoemia. Glomerulosclerosis. Fibrosis Intersticial. Necrosis Tubular. Nefropatía.

1 INTRODUCTION

Renal diseases in horses are considered relatively uncommon compared with disorders of the digestive and musculoskeletal systems. However, they are of considerable clinical importance because of their high morbidity and frequently guarded prognosis, as many animals are diagnosed only in the advanced stages of the disease. The kidneys perform essential functions in maintaining homeostasis, including the excretion of metabolic waste products, regulation of fluid, electrolyte, and acid-base balance, as well as erythropoietin production and vitamin D activation. Loss of renal function results in azotemia, electrolyte disturbances, uremia, and systemic impairment, directly affecting the animal's clinical condition (JOCELYN, 2020; CAPUTO *et al.*, 2022).

Acute kidney injury (AKI) is characterized by an abrupt reduction in the glomerular filtration rate and may result from ischemic, nephrotoxic, infectious, or obstructive causes. In contrast, chronic kidney disease (CKD) results from the progressive and irreversible loss of renal function and is characterized by permanent damage to the renal parenchyma and a gradual decline in the functional capacity of the kidneys (GEOR; HARRIS; DIVERS, 1987; CAPUTO *et al.*, 2022). Among the causes of renal impairment in horses are infectious processes, exposure to nephrotoxic agents, circulatory disturbances, and urinary tract obstructions, including urolithiasis, a condition that may progress to renal failure if not diagnosed early (JOCELYN, 2020).

Laboratory evaluation is an essential component in the investigation of renal diseases. Increased serum urea and creatinine concentrations reflect a reduced glomerular filtration rate; however, these markers have limited sensitivity for detecting renal injury in the early stages. Urinalysis complements this assessment by providing information on urinary concentrating ability and enabling the identification of abnormalities such as proteinuria, cylindruria, bacteriuria, and crystalluria. In horses, the presence of calcium carbonate crystals in the urine is considered a physiological characteristic of the species and should be interpreted in conjunction with other clinical and laboratory findings (THRALL *et al.*, 2015).

Although laboratory tests are essential for diagnostic suspicion and monitoring clinical progression, histopathological evaluation allows characterization of the nature and extent of renal lesions, contributing to the correlation between microscopic findings and the observed clinical and laboratory abnormalities. The integration of these findings provides a better

understanding of disease progression and offers greater confidence in establishing the definitive diagnosis (CAPUTO *et al.*, 2022; JOCELYN, 2020).

2 OBJECTIVE

Given the scarcity of reports correlating clinical, laboratory, and histopathological findings in horses with bilateral renal involvement, the present study aimed to describe a case of renal disease in a horse by associating the biochemical and histopathological findings observed in both kidneys, with emphasis on the microscopic changes responsible for confirming the diagnosis.

3 CASE REPORT

An 8-year-old male Quarter Horse was presented to the Veterinary Teaching Hospital of the University of Franca (UNIFRAN, São Paulo, Brazil) with a clinical suspicion of colic, exhibiting severe abdominal pain, discomfort, and difficulty urinating. Laboratory evaluation revealed increased serum urea and creatinine concentrations, consistent with impaired renal function. Despite the therapeutic interventions instituted, the clinical condition progressively deteriorated, and the animal was subsequently euthanized. During necropsy, both kidneys were collected and submitted for histopathological evaluation.

Gross examination revealed that the right kidney was enlarged, with easy capsular stripping and prominent blood vessels. On cut section, the cortex was diffusely reddened and contained multiple whitish streaks. The left kidney was atrophic and irregular, with marked dilation of the medulla and renal pelvis, associated with the presence of yellowish gelatinous material and fine brownish granular deposits adhered to the surface of the renal pelvis (Figure 1).

Figure 1

Comparative gross appearance of the kidneys, demonstrating marked asymmetry in size. Right: markedly enlarged right kidney. Left: reduced-size (atrophic) left kidney



Source: Personal archive, Veterinary Teaching Hospital, University of Franca (UNIFRAN).

Microscopically, the right kidney exhibited diffuse acute tubular injury characterized by swelling and vacuolization of the tubular epithelium, tubular lumina filled with necrotic cellular debris, hyaline casts, erythrocyte casts, and numerous intratubular calcium carbonate crystals, with preservation of the tubular basement membrane. In addition, a multifocal moderate lymphoplasmacytic interstitial inflammatory infiltrate, mild interstitial fibrosis, focal tubular hyperplasia, hypertrophied glomeruli with thickening of Bowman's capsule and glomerular capillary loops, as well as diffuse congestion and a focal area of medullary hemorrhage were observed (Figure 2).

Figure 2

Photomicrograph of the right kidney from a horse, showing multiple proximal and distal convoluted tubules with microvacuolated epithelium, epithelial cell detachment, and occasional tubular dilation containing calcium carbonate crystals (hematoxylin and eosin stain, ×20 objective; Leica microscope)

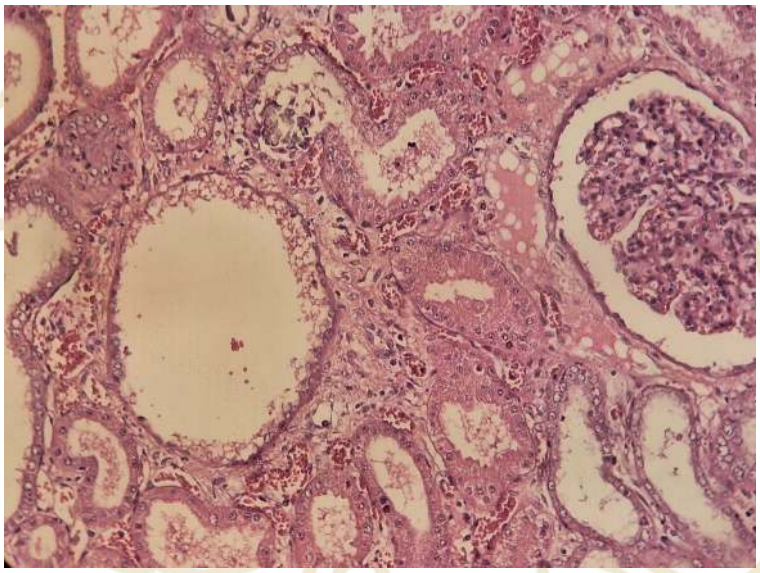

Source: Personal archive, Veterinary Teaching Hospital, University of Franca (UNIFRAN).

Microscopically, the left kidney exhibited lesions consistent with advanced chronic kidney disease, characterized by extensive tubular loss, remaining ectatic tubules lined by flattened epithelium, intraluminal hyaline material, and neutrophilic infiltrate. The renal parenchyma was extensively replaced by fibrous connective tissue associated with a diffuse marked lymphoplasmacytic inflammatory infiltrate. The glomeruli exhibited retraction, thickening of the glomerular capillary loops, and varying degrees of glomerular fibrosis, in addition to diffuse congestion and hyperplasia of the renal pelvic mucous glands (Figure 3).

Figure 3

Photomicrograph of the left kidney from a horse, showing multiple glomeruli, some retracted, with areas of segmental to global glomerulosclerosis associated with expansion of the interstitium by fibrous connective tissue (hematoxylin and eosin stain, ×20 objective; Leica microscope)

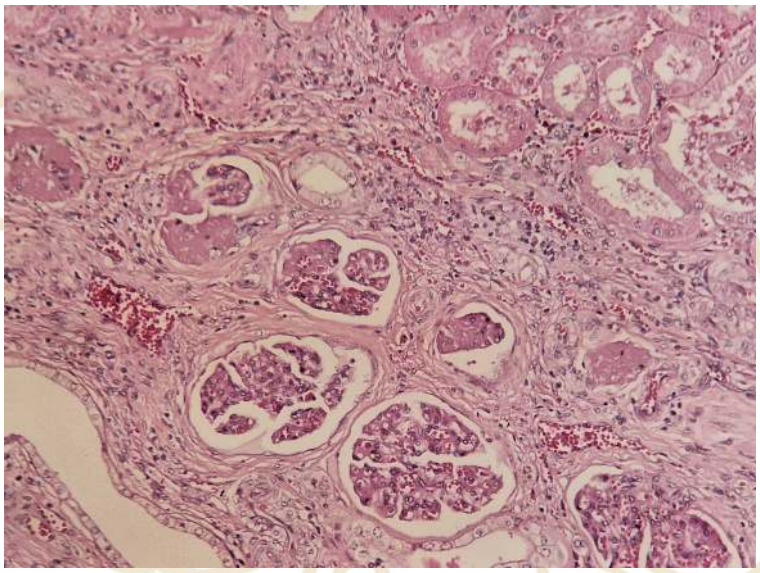

Source: Personal archive, Veterinary Teaching Hospital, University of Franca (UNIFRAN).

The histopathological diagnosis of the right kidney was nephrotoxic acute tubular injury associated with numerous intratubular calcium carbonate crystals and multifocal chronic lymphoplasmacytic nephritis, whereas the left kidney exhibited severe diffuse chronic interstitial nephritis accompanied by neutrophilic tubulitis, cystic tubular dilation, and diffuse segmental to global glomerulosclerosis. Collectively, these findings indicated the coexistence of acute kidney injury superimposed on advanced chronic renal lesions, consistent with obstructive nephropathy associated with urolithiasis, ultimately resulting in severe renal failure and an unfavorable clinical outcome.

4 DISCUSSION

Renal diseases in horses are relatively uncommon but are associated with high morbidity due to their generally delayed diagnosis and the limited regenerative capacity of renal tissue. Clinical signs usually become apparent only after substantial loss of renal function because of the kidneys' considerable functional reserve (CAPUTO *et al.*, 2022;

JOCELYN, 2020). In the present case, increased serum urea and creatinine concentrations, together with the unfavorable clinical progression, indicated significant impairment of renal function, which was subsequently confirmed by the histopathological evaluation of both kidneys.

According to Geor, Harris, and Divers (1987), the interpretation of serum urea and creatinine concentrations should be performed in conjunction with the clinical and laboratory findings, as these markers reflect reductions in the glomerular filtration rate only at relatively advanced stages. In horses, increased serum concentrations generally indicate substantial loss of renal function and may occur in both acute kidney injury and chronic kidney disease (GEOR; HARRIS; DIVERS, 1987). In the present case, the elevated serum concentrations, together with the histopathological findings, reinforced the diagnosis of advanced bilateral renal impairment.

Histopathological evaluation of the kidneys revealed the coexistence of lesions consistent with chronic kidney disease and acute kidney injury. The presence of glomerulosclerosis, interstitial fibrosis, and tubular atrophy indicated a chronic process, whereas tubular degeneration and necrosis suggested a superimposed acute insult. This combination has been described in horses with progressive renal disease, in which acute episodes accelerate the decline of renal function (GEOR; HARRIS; DIVERS, 1987; JOCELYN, 2020). In the present case, the correlation between the histopathological findings and the biochemical abnormalities further supported the occurrence of acute kidney injury superimposed on a previously damaged renal parenchyma, explaining the severity of the clinical condition.

Among the microscopic alterations, interstitial fibrosis, glomerulosclerosis, and tubular atrophy were particularly noteworthy, as these lesions are indicative of chronicity and are associated with the irreversible loss of functional nephrons. These changes promote remodeling of the renal parenchyma, impair glomerular filtration, and contribute to the development of azotemia. In horses with chronic kidney disease, these findings are closely associated with the progressive decline in renal function and are considered important markers of irreversibility when diffusely distributed (CAPUTO *et al.*, 2022; GEOR; HARRIS; DIVERS, 1987).

Tubular degeneration and necrosis observed in both kidneys indicated injury to the tubular epithelium, a hallmark of acute kidney injury. These alterations impair tubular reabsorption and urinary concentrating ability, contributing to reduced renal function and the development of azotemia. According to DIVERS (2022) and VAN GALEN, OLSEN; SIWINSKA (2022), acute tubular necrosis in horses may coexist with chronic renal lesions, making it difficult to distinguish between these processes based solely on clinical and laboratory evaluation. In the present case, the association of tubular necrosis with interstitial fibrosis and glomerulosclerosis further supported the occurrence of acute kidney injury superimposed on a previously compromised kidney, explaining the unfavorable clinical outcome.

In the present case, another relevant finding was the presence of abundant calcium carbonate crystals within the tubular lumina. Although these crystals may occur physiologically in horses, extensive deposits associated with tubular and interstitial lesions suggest renal impairment. Evidence indicates that their formation is generally associated with pre-existing chronic kidney disease rather than representing the primary cause of the disorder. Therefore, in this case, the crystals most likely represented a secondary finding resulting from renal damage, although they may have contributed to the progression of tubular injury. This interpretation is supported by the bilateral distribution of the lesions and the presence of histopathological changes consistent with chronicity (OLSEN; VAN GALEN, 2022; ECEIM CONSENSUS STATEMENT, 2024).

Although clinical evaluation and laboratory testing are essential in the investigation of renal disease in horses, definitive characterization of renal lesions depends on histopathological examination. In the present case, the association between azotemia and the microscopic findings demonstrated extensive renal involvement, including glomerulosclerosis, interstitial fibrosis, tubular atrophy, and tubular necrosis, alterations that explain the reduction in glomerular filtration and the unfavorable clinical outcome. According to the European College of Equine Internal Medicine (ECEIM) Consensus Statement, histopathology remains the reference standard for the characterization of renal lesions. However, because renal biopsy has limited indications in horses, many definitive diagnoses are established only at necropsy, as occurred in the present case (ECEIM CONSENSUS STATEMENT, 2024).

These findings reinforce that the isolated interpretation of biochemical markers may underestimate the complexity of renal lesions. Although serum creatinine and urea concentrations are widely used to assess renal function, their elevation occurs only after substantial loss of renal function and does not necessarily reflect the extent of histopathological damage. Therefore, the integration of clinical, laboratory, and pathological findings is essential for a more comprehensive evaluation of renal disease in horses (DIVERS, 2022). Despite advances in the investigation of serum and urinary biomarkers for the early diagnosis of renal disease, their use remains limited in routine clinical practice, making histopathology an essential tool for confirming the diagnosis and understanding the progression of equine nephropathies.

The findings of the present case reinforce the multifactorial nature of renal diseases in horses and highlight the importance of correlating clinical, laboratory, and histopathological data. Although clinical signs and azotemia indicate renal impairment, they do not allow determination of the underlying etiology or differentiation between acute and chronic processes when considered in isolation. In this context, histopathological evaluation was essential for characterizing the renal lesions and demonstrating the coexistence of degenerative, inflammatory, and fibrotic changes, providing a more comprehensive understanding of the disease pathophysiology (CAPUTO *et al.*, 2022; ECEIM CONSENSUS STATEMENT, 2024).

This case report highlights the scarcity of publications correlating the pathological findings of renal disease in horses. The characterization of renal lesions in association with laboratory findings expands the current understanding of the disease and may assist veterinarians in the interpretation of similar cases. Therefore, case reports remain valuable by documenting rarely described histopathological features and the coexistence of acute and chronic lesions, thereby contributing to a better understanding of the progression of equine nephropathies and to the improvement of diagnostic approaches (DIVERS, 2022; OLSEN; VAN GALEN, 2022).

5 CONCLUSION

The integration of clinical, laboratory, and histopathological findings was fundamental for the characterization of bilateral renal disease in this horse. The coexistence of lesions

consistent with acute kidney injury and chronic kidney disease highlights the importance of histopathological evaluation in understanding the extent and progression of renal disease, contributing to the definitive diagnosis and to a better understanding of the pathophysiology of these disorders in the species.

REFERENCES

CAPUTO, J. T. et al. Insuficiência renal em equinos. *PubVet*, Maringá, v. 16, n. 5, e1117, p. 1-10, 2022. DOI: https://doi.org/10.31533/pubvet.v16n05a1117.

DIVERS, T. J. Relevant equine renal anatomy, physiology, and mechanisms of acute kidney injury. *Veterinary Clinics of North America: Equine Practice*, v. 38, n. 1, p. 1-12, 2022. DOI: https://doi.org/10.1016/j.cveq.2021.11.001.

EUROPEAN COLLEGE OF EQUINE INTERNAL MEDICINE (ECEIM). ECEIM consensus statement on equine kidney disease. *Journal of Veterinary Internal Medicine*, 2024.

GEOR, R. J.; HARRIS, P. A.; DIVERS, T. J. Equine acute renal failure. *Veterinary Clinics of North America: Equine Practice*, Philadelphia, v. 3, n. 3, p. 531-543, 1987.

JOCELYN, N. Kidney disease in the horse. *Equine Health*, v. 51, p. 20-23, 2020.

OLSEN, E.; VAN GALEN, G. Chronic renal failure: causes, clinical findings, treatments and prognosis. *Veterinary Clinics of North America: Equine Practice*, v. 38, n. 1, p. 25-46, 2022. DOI: https://doi.org/10.1016/j.cveq.2021.11.003.

THRALL, M. A. et al. *Hematologia e bioquímica clínica veterinária*. 2. ed. Rio de Janeiro: Guanabara Koogan, 2015.

VAN GALEN, G.; OLSEN, E.; SIWINSKA, N. Biomarkers of kidney disease in horses: a review of the current literature. *Animals*, v. 12, n. 19, p. 2678, 2022. DOI: https://doi.org/10.3390/ani12192678.