



MANDIBULAR BONE EROSION ASSOCIATED WITH HYALURONIC ACID FILLER: CBCT CASE REPORT

EROSÃO ÓSSEA MANDIBULAR ASSOCIADA AO PREENCHIMENTO COM ÁCIDO HIALURÔNICO: RELATO DE CASO POR TCFC (CBCT)

EROSIÓN ÓSEA MANDIBULAR ASOCIADA AL RELLENO CON ÁCIDO HIALURÓNICO: REPORTE DE CASO MEDIANTE TCFC (CBCT)



10.56238/bocav25n74-025

**José Roberto Alves Moreira¹, Henrique Barcelos Brandão², Ana Thais Bagatini³,
Marcos Cesar Pitta⁴, Luiz Gonzaga Gandini Junior⁵, Ary dos Santos Pinto⁶**

ABSTRACT

We report a case of bone erosion in the mental region associated with hyaluronic acid (HA) injection for cosmetic purposes, incidentally identified in a patient undergoing orthodontic treatment with miniscrew-assisted rapid palatal expansion (MARPE). This case offers rare sequential radiographic documentation using cone-beam computed tomography (CBCT) both before and after HA injection, along with intraoperative confirmation of the lesion. These findings provide further support for the hypothesis of HA-induced bone resorption. This report underscores the critical role of imaging in interdisciplinary clinical practice and contributes meaningful evidence regarding the potential adverse effects of facial fillers on underlying osseous structures.

Keywords: Orthodontics. Cone-Beam Computed Tomography. PET CT Scan. Palatal Expansion Technique. Orthodontic Anchorage Procedures. Hyaluronic Acid.

RESUMO

Relatamos um caso de erosão óssea na região mental associada à injeção de ácido hialurônico (AH) para fins estéticos, identificada incidentalmente em uma paciente submetida a tratamento ortodôntico com expansão rápida da maxila assistida por mini-implantes

¹ Master's degree of Science in Orthodontics. Universidade Estadual Paulista (UNESP). São Paulo, Brazil. E-mail: jose.r.moreira@unesp.br Orcid: <https://orcid.org/0009-0003-1790-2051>

Lattes: <http://lattes.cnpq.br/5245525150765815>

² Master's degree of Science in Orthodontics. Universidade Estadual Paulista (UNESP). São Paulo, Brazil. E-mail: henrique.brandao@unesp.br Orcid: <https://orcid.org/0000-0002-7238-7078>

Lattes: <https://lattes.cnpq.br/2053748244308327>

³ Master's degree of Science in Orthodontics. Universidade Estadual Paulista (UNESP). São Paulo, Brazil. E-mail: ana.bagatini@unesp.br Orcid: <https://orcid.org/0000-0002-0517-2595>

Lattes: <http://lattes.cnpq.br/4107446824355207>

⁴ MSc in Oral and Maxillofacial Surgery. Private Practice. São Paulo, Brazil. E-mail: mc.pitta@uol.com.br Orcid: <https://orcid.org/0000-0003-2671-0732> Lattes: <http://lattes.cnpq.br/3487914682644475>

⁵ Professor. Universidade Estadual Paulista (UNESP). São Paulo, Brazil. E-mail: luiz.gandini@unesp.br Orcid: <https://orcid.org/0000-0001-8656-6010> Lattes: <http://lattes.cnpq.br/6493049604923160>

⁶ Professor. Universidade Estadual Paulista (UNESP). São Paulo, Brazil. E-mail: ary.santos-pinto@unesp.br Orcid: <https://orcid.org/0000-0003-3355-0001> Lattes: <http://lattes.cnpq.br/6562540057111580>

(MARPE). Este caso apresenta uma rara documentação radiográfica sequencial por meio de tomografia computadorizada de feixe cônico (TCFC), realizada antes e após a aplicação do AH, além da confirmação intraoperatória da lesão. Esses achados fornecem suporte adicional à hipótese de reabsorção óssea induzida pelo ácido hialurônico. O presente relato destaca o papel fundamental dos exames de imagem na prática clínica interdisciplinar e contribui com evidências relevantes acerca dos potenciais efeitos adversos dos preenchedores faciais sobre as estruturas ósseas subjacentes.

Palavras-chave: Ortodontia. Tomografia Computadorizada de Feixe Cônico. PET-CT. Técnica de Expansão Palatina. Procedimentos de Ancoragem Ortodôntica. Ácido Hialurônico.

RESUMEN

Se reporta un caso de erosión ósea en la región mentoniana asociada a la inyección de ácido hialurónico (AH) con fines estéticos, identificado de forma incidental en una paciente sometida a tratamiento ortodóncico con expansión rápida del maxilar asistida por miniimplantes (MARPE). Este caso presenta una rara documentación radiográfica secuencial mediante tomografía computarizada de haz cónico (TCFC), realizada antes y después de la aplicación de AH, además de la confirmación intraoperatoria de la lesión. Estos hallazgos aportan mayor respaldo a la hipótesis de reabsorción ósea inducida por el ácido hialurónico. El presente informe destaca el papel fundamental de las técnicas de imagen en la práctica clínica interdisciplinaria y contribuye con evidencia relevante sobre los posibles efectos adversos de los rellenos faciales en las estructuras óseas subyacentes.

Palabras clave: Ortodoncia. Tomografía Computarizada de Haz Cónico. PET-CT. Técnica de Expansión Palatina. Procedimientos de Anclaje Ortodóncico. Ácido Hialurónico.

1 INTRODUCTION

Miniscrew-Assisted Rapid Palatal Expansion (MARPE)¹ has established itself as an effective alternative for the treatment of transverse maxillary deficiencies in young and adult patients, promoting predominantly skeletal movements with minimal dentoalveolar repercussions. The protocol often involves the use of cone beam computed tomography (CBCT) both in planning and post-treatment evaluation, providing a detailed view of the craniofacial bone structures involved in the procedure.²

At the same time, the use of hyaluronic acid (HA)-based dermal fillers has become widely popular in minimally invasive facial aesthetic procedures, especially in the mental region.³ Although they are considered safe, reports in the literature have described rare cases of complications, including localized bone resorption, possibly from chronic inflammatory reactions or vascular compression.^{4,5}

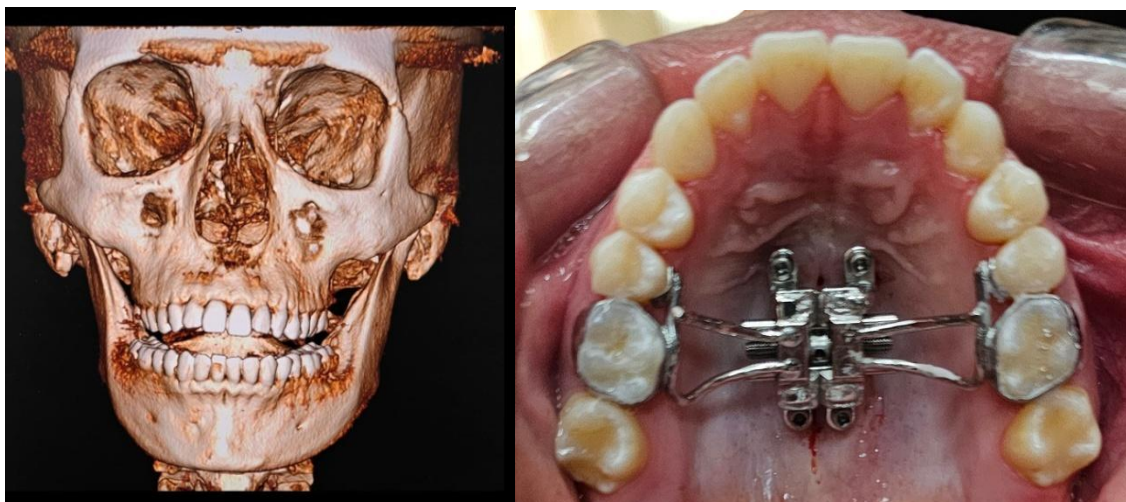
In this context, we report a clinical case of bone erosion in the mandibular body region, incidentally identified by tomography performed for post-expansion evaluation with MARPE. The patient had a history of HA application in the mental region, and the radiographic finding suggests a possible association between the aesthetic procedure and the observed bone resorption. This case reinforces the importance of imaging evaluation and interdisciplinary dialogue between orthodontists and orofacial aesthetics professionals.

2 CASE REPORT

A 21-year-old female patient sought orthodontic treatment with the chief complaint of anterior open bite, masticatory difficulty, and a narrow smile. Clinical examination and cephalometric analysis revealed a constricted maxilla with moderate transverse deficiency, a Class I maxillomandibular dental relationship, mild mandibular retrusion, and no facial asymmetries.^{6,7} CBCT was requested for treatment planning and demonstrated stage C maturation of the midpalatal suture according to Angilieri's classification.² Considering the patient's advanced age for conventional rapid palatal expansion using a Hyrax or Haas-type expander, MARPE was selected as the treatment approach.⁸ A MARPE EX 13 mm expander (Peclab) was installed and four mini-implants anchored in: two anterior (code: 5500) HS MARPE 1.8 × 7 × 8 mm and two posterior (code: 2926) HS MARPE 1.8 × 7 × 4 mm orthodontic mini-implants (Peclab, Belo Horizonte, Brazil), registered with ANVISA under number 80041470004. The mini-implants were positioned in the paramedian region of the palate. Immediately after the success achieved through this procedure, orthodontic completion with aligners was started (Fig. 1A, B).

Figure 1

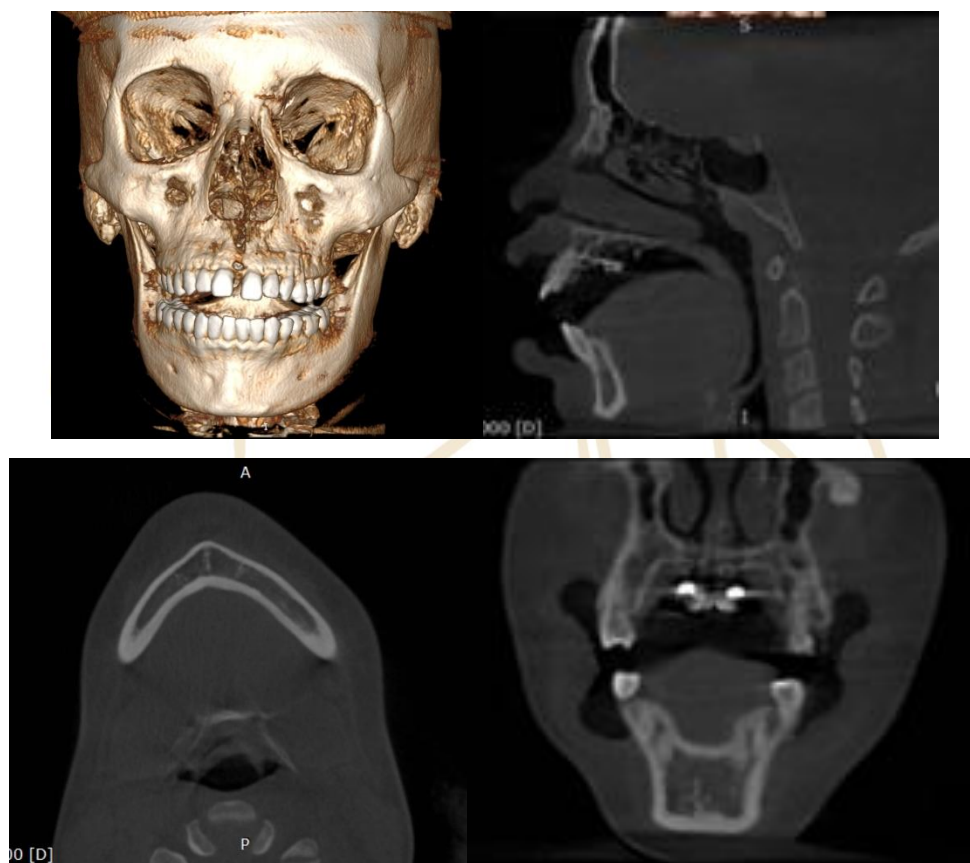
A. Initial 3D CBCT reconstruction performed for planning of the MARPE device. B. Intraoral occlusal photograph showing the MARPE appliance installed, anchored by four mini-implants



Activation was performed according to protocol (1/4 turn per day), totaling 18 activations in approximately 19 days.¹ The success of the procedure was confirmed clinically by the diastema between the central incisors, and radiographically, by the opening of the midpalatal suture observed in the follow-up CBCT (Fig. 2A-D). After eight months transverse stability was achieved and removal of the MARPE device was planned. A new CBCT was requested to evaluate bone consolidation. The objective of scan was to reevaluate the bone anatomy before removal of the mini-implants.⁹

Figure 2

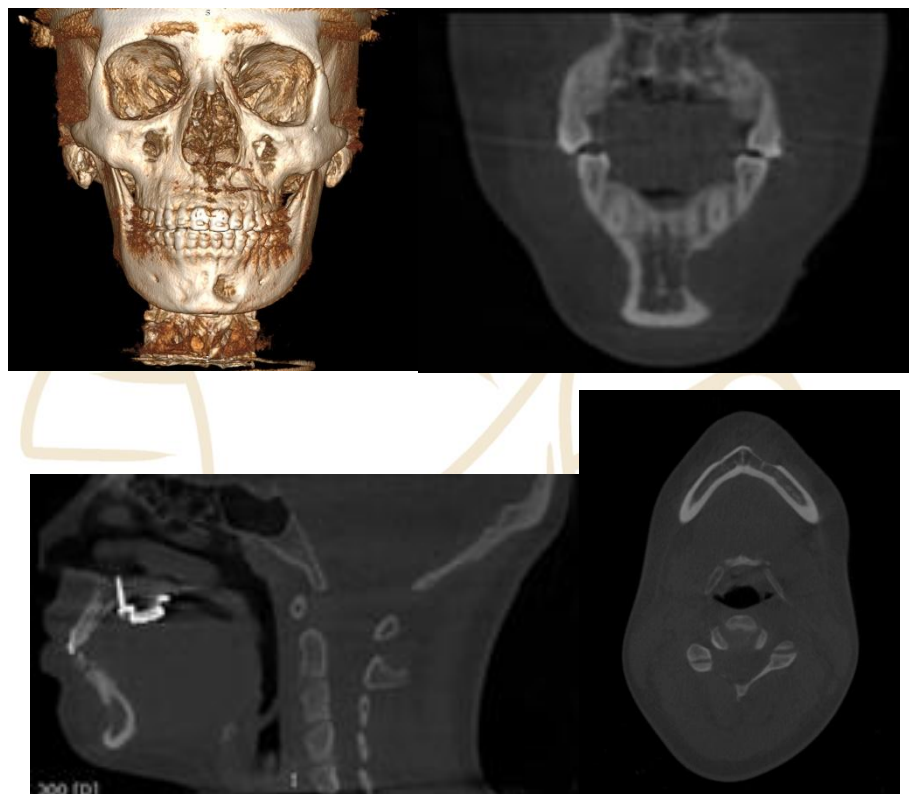
A. Post-expansion 3D CBCT confirming midpalatal suture opening. 2A. Sagittal CBCT slice obtained 15 days before soft tissue filler injection, showing intact mandibular symphysis. 3A. Axial slice confirming no bone erosion in the mentum prior to filler placement. 4A. Coronal CBCT image showing intact cortical and trabecular structure of the anterior mandible before aesthetic procedures



In the analysis of the tomographic image, a well-defined area of bone resorption 1.32cm high x 1.52cm wide x 2.79mm deep was observed in the mandibular body. The lesion showed partial loss of the buccal cortex, with evident reabsorption of the trabecular bone, characterizing an erosive process compatible with chronic and localized involvement of the bone tissue (Fig. 3A-D). When questioned about it, the patient reported no history of trauma in that region and denied pain, paresthesia, or symptoms suggestive of local inflammation. However, she reported a history of application of 1ml of HA in the mental region 7.5 months prior, 15 days after the MARPE locking, by a professional specialized in orofacial harmonization.

Figure 3

A. CBCT 3D reconstruction performed 8 months after MARPE treatment and 7.5 months after HA filler injection in the mental region, revealing erosive lesion in the mentum. 3B–D. Axial, sagittal, and coronal CBCT slices showing the extent of bone erosion in the mandibular symphysis



Given the finding, the patient was referred to an endodontics specialist, who assessed the pulp vitality of the adjacent teeth by periapical and panoramic radiographs. The studies were negative for necrosis, and the patient was then advised to also undergo an evaluation by a bucomaxillofacial surgeon to consult on the best course of action.

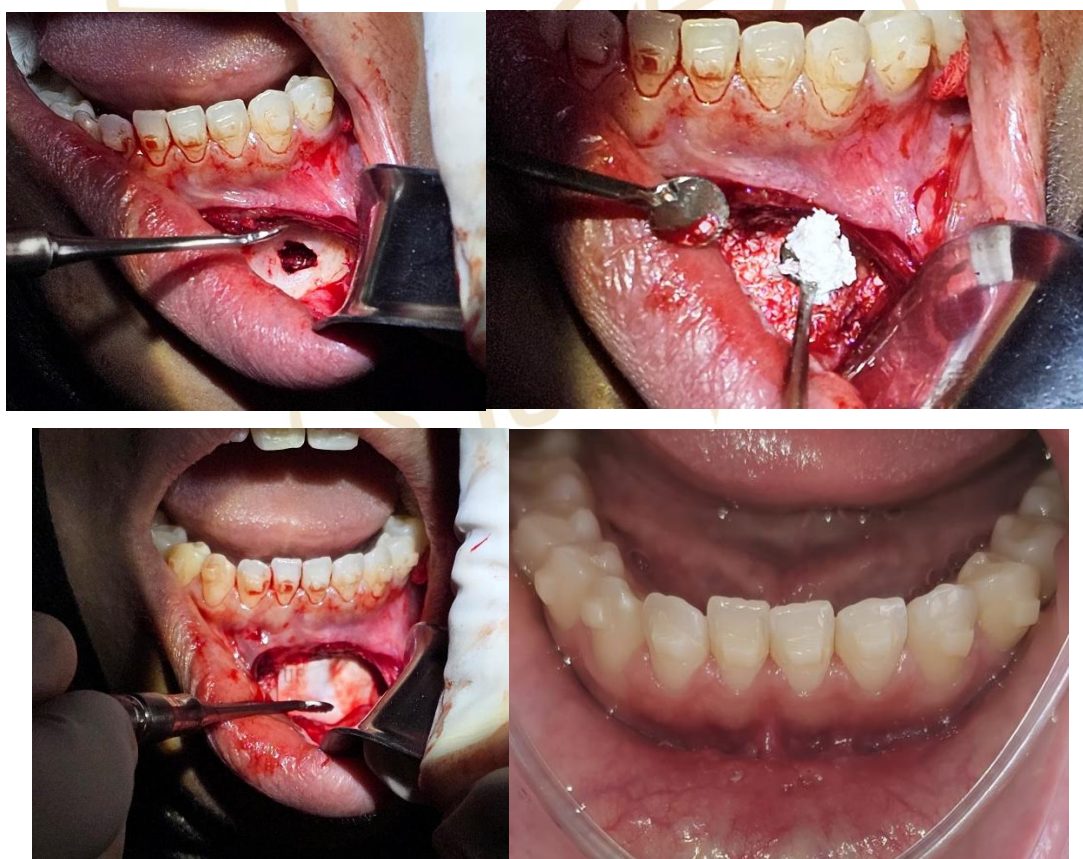
PET/CT scans performed to assess the presence of granulomatous lesions in other regions of the body did not show changes compatible with this condition, ruling out systemic inflammatory processes. These findings hypothetically suggest that the observed lesion may be related to the pressure exerted by the filling material with highly cross-linked hyaluronic acid.¹⁰

Ultimately, surgery was decided due to the size of the lesion and concern for inducing aseptic necrosis in the teeth involved in the adjacent area (teeth 31, 32, and 33). During exploratory surgery, signs of reabsorption of the buccal cortex as well as the trabecular area measuring 1.32cm x 1.52cm x 2.79mm was found in the mental region on the left side. In the region on the right side, three foveas without invasion of the trabecular only in the buccal cortex were also detected. after being curetted, as well as the one on the left side, were filled

with Geistlich Bio-Oss® (spongy granules 0.25–1 mm, 2 g; Geistlich Pharma AG, Wolhusen, Switzerland), with ANVISA registration number 80696930002 and Geistlich Bio-Gide® collagen membrane (Geistlich Pharma AG, Wolhusen, Switzerland) registered with ANVISA under number 80696930003, sutured and surgery completed with guided radiographic follow-up after 3 months. No materials were collected for examinations, as reabsorption occurred due to pressure.⁴ (Fig. 4A-D).

Figure 4

A1. Exploratory surgery revealing a buccal cortical bone defect and exposure of trabecular bone in the region of the filler application. A2. Bone cavity filled with deproteinized bovine bone graft (Bio-Oss®, Geistlich Pharma, Switzerland). A3. Adaptation of the resorbable membrane over the grafted area. A4. Clinical aspect after 7 days of healing and suture removal



3 DISCUSSION

Recent evidence suggests that bone resorption associated with the use of hyaluronic acid-based dermal fillers may be more prevalent than previously reported. Studies have shown that a significant proportion of patients develop bony changes in the mental region after such procedures, highlighting the need for careful evaluation and appropriate

radiographic follow-up.^{11,12} The present clinical case describes an incidental finding, identified by computed tomography requested for orthodontic purposes after completion of the active expansion phase with MARPE. The temporal association with the application of HA in this region suggests a possible causal relationship, as discussed in previous reports.^{4,5,11,12}

Furthermore, as highlighted by Bass et al.,³ the injection technique is critical to achieving excellent results with dermal fillers. Techniques such as threading, fanning, cross-hatching, bleb, and pillar must be mastered to ensure the safety and efficacy of the procedure. Technical execution can only match, but not exceed, the quality of the aesthetic analysis. In the case presented, the absence of clinical symptoms and the incidental detection of the bone lesion highlight the importance of a careful technical approach and a detailed aesthetic evaluation to minimize risks and complications associated with the use of dermal fillers.³

Corroborating this evidence, Guo et al. (2020)⁴ reported a series of Asian cases in a retrospective cohort study that identified bone resorption in the mental region following HA filler application. The authors observed that, even in asymptomatic patients, structural bone changes could occur insidiously. The study raises the hypothesis that the prolonged presence of the filler, combined with the pressure exerted on the cortical bone of the mental region, may trigger an unexpected resorption process.

The case reported by Nakagawa et al. (2022)⁵ described a patient with skeletal Class II deformity and significant bone resorption in the mental region, associated with prolonged use of hyaluronic acid. The authors suggest that chronic compression and/or low-grade inflammatory reactions induced by the material may lead to adverse bone remodeling, particularly when the filler is applied deeply or in close proximity to the periosteum.

Although the radiographic finding raises the hypothesis of bone remodeling associated with the use of dermal fillers, there is insufficient evidence in the literature to state that such alterations require intervention or specific imaging monitoring in healthy patients without symptoms. Therefore, the indication for computed tomography should always be based on clear clinical criteria, respecting the principles of justification and optimization of radiographic exposure.

From an anatomical perspective, the mental region comprises dense cortical bone with limited vascularization, rendering it more susceptible to necrosis or bone resorption when exposed to chronic pressure—either from the intrinsic synergistic action of the mentalis muscle or from vascular compromise. Although HA is widely regarded as a biocompatible and resorbable material, its prolonged presence—particularly in cases of repeated applications—may induce alterations in bone architecture.⁴

This case underscores the importance of an interdisciplinary approach, particularly involving orthodontists, radiologists, and facial aesthetic practitioners. It also emphasizes the critical role of comprehensive documentation of the patient's aesthetic history. Moreover, it highlights the diagnostic value of cone-beam computed tomography, not only as an essential tool for orthodontic planning but also for the identification of incidental findings with potential medical or surgical relevance.

4 CONCLUSION

This case report illustrates the importance of radiographic evaluation using computed tomography in patients undergoing orthodontic treatment, particularly when devices such as MARPE are employed. The incidental detection of a bone lesion in the mental region, associated with prior HA filler application, highlights the necessity for integration across multiple healthcare disciplines, including orthodontics, radiology, and facial aesthetics. Clinical and radiographic follow-up is essential in such cases and reinforces the need for greater awareness regarding the potential adverse effects of dermal fillers on deep bony structures.

REFERENCES

1. Angelieri, F., Cevidanes, L. H. S., Franchi, L., Gonçalves, J. R., Benavides, E., & McNamara, J. A., Jr. (2013). Midpalatal suture maturation: Classification method for individual assessment before rapid maxillary expansion. *American Journal of Orthodontics and Dentofacial Orthopedics*, 144(5), 759–769. <https://doi.org/10.1016/j.ajodo.2013.04.022>
2. Angell, E. H. (1860). Treatment of irregularity of the permanent or adult teeth. *Dental Cosmos*, 1, 540–544, 599–600.
3. Arnett, G. W., & Bergman, R. T. (1993). Facial keys to orthodontic diagnosis and treatment planning. Part I. *American Journal of Orthodontics and Dentofacial Orthopedics*, 103(4), 299–312. [https://doi.org/10.1016/0889-5406\(93\)70010-L](https://doi.org/10.1016/0889-5406(93)70010-L)
4. Bass, L. S. (2015). Injectable filler techniques for facial rejuvenation, volumization, and augmentation. *Facial Plastic Surgery Clinics of North America*, 23(4), 479–488. <https://doi.org/10.1016/j.fsc.2015.07.004>
5. Cantarella, D., Dominguez-Mompell, R., Mallya, S. M., Moschik, C., & Siciliani, G. (2018). Changes in the midpalatal and pterygopalatine sutures induced by micro-implant-supported skeletal expander, analyzed with a novel 3D method based on CBCT imaging. *Progress in Orthodontics*, 19(1), Article 4.
6. Guo, X., Zhao, J., Song, G., Zong, X., Zhang, D., Lai, C., & Jin, X. (2020). Unexpected bone resorption in mentum induced by the soft-tissue filler hyaluronic acid: A preliminary

- retrospective cohort study of Asian patients. *Plastic and Reconstructive Surgery*, 146(2), 147e–155e. <https://doi.org/10.1097/PRS.00000000000006979>
7. Guo, X., Zong, X., Song, G., Zhao, J., Lai, C., Zhang, D., & Jin, X. (2024). Would hyaluronic acid-induced mental bone resorption be a concern? A prospective controlled cohort study and an updated retrospective cohort study. *International Journal of Surgery*, 110(3), 1502–1510. <https://doi.org/10.1097/JS9.0000000000000955>
 8. Haas, A. J. (1961). Rapid expansion of the maxillary dental arch and nasal cavity by opening the midpalatal suture. *Angle Orthodontist*, 31(2), 73–90.
 9. Karam, M. B., Baratto, L., Sheikhabahaei, S., Werner, R. A., Solnes, L. B., Rowe, S. P., & et al. (2021). Role of 18F-FDG PET in the management of sarcoidosis and other granulomatous diseases. *AJR. American Journal of Roentgenology*, 216(2), 285–294. <https://doi.org/10.2214/AJR.20.23430>
 10. Lee, K. J., Park, Y. C., Park, J. Y., & Hwang, W. S. (2010). Mini screw assisted nonsurgical palatal expansion before orthognathic surgery for a patient with severe mandibular prognathism. *American Journal of Orthodontics and Dentofacial Orthopedics*, 137(6), 830–839.
 11. Nakagawa, T., Ono, S., Sakuma, M., & et al. (2022). A case of bone resorption in the mentum caused by HA filler in a patient with skeletal Class II jaw deformity. *Oral Radiology*, 38(1), 185–190.
 12. Shu, K. Y., Feng, W. R., & Zhao, J. L. (2024). Bone resorption of HA fillers injection induced in chin augmentation: A retrospective study. *Journal of Craniofacial Surgery*. Advance online publication. <https://doi.org/10.1097/SCS.00000000000011033>
- 